



PATIENT
Myles Marsh

PRESENTING CLINICAL SIGNS
 History: Grade 5/6 heart murmur. Heavy breathing.
 -Blood Pressure: 136, 146, 158, 164, 147mmHg.

SPECIES
Canine

ELECTROCARDIOGRAPHIC FINDINGS *Note: Single lead ECGs are evaluated as a rhythm strip. Morphology/MEA cannot be definitively commented on.
 A single lead ECG is available; 50mm/s, 20mm/mV. The average heart rate is 115bpm (range 107-120bpm). The rhythm is sinus in origin, with a p for every QRS complex and vice versa. The P and QRS morphologies are positive. No ectopic beats, pauses or dysrhythmias observed.
 ECG diagnosis: Normal sinus rhythm with respiratory variation.

BREED
Airdale

SEX
Male Neutered

AGE
10 years

ECHOCARDIOGRAM FINDINGS

2D, m-mode, color flow and doppler imaging is available. Diffuse thickening of mitral valve leaflets with mild prolapse into the left atrial lumen. Severe eccentric mitral regurgitation with severe left atrial dilation. Normal MR velocity. Mild LV dilation with hyperdynamic myocardial function. The tricuspid valve appears thickened with mild to moderate TR. Normal velocity. No significant right heart enlargement. The pulmonic and aortic valves are normal in morphology and mobility. Normal aortic and pulmonic outflow velocities with laminar flow. No AI/PI. No pericardial or pleural effusion noted. No obvious cardiac masses.

WEIGHT
70.8lbs

CARDIAC CHART

INTERPRETED BY

Maggie Machen
Lamy, DVM, DACVIM
(Cardiology)

IMAGING PERFORMED BY

Jenna Walsh, CVT

HOSPITAL NAME

Four Corners
Veterinary Clinic

REFERRING VET

Dr. Dull

INVOICE

24566

DATE

6/3/22

CANINE CARDIAC PARAMETERS	MR VMAX (m/s)	TR VMAX (m/s)	LA/AO (Boon method)	LA/AO (Heart Base; Swe)	FS (%)	EF (%)	EPSS (cm)
NORMAL PARAMETER	4.5-5.5	<2.7	1.3	<1.6	28-40	40-100	<0.6
PATIENT	5.3	2.5	NM	2.0	36	65	NM
CANINE CARDIAC PARAMETERS	HR (BPM)	AV VMAX (m/s)	PV MAX (m/s)	BODY WEIGHT (kg)	LA 2D short axis Base view (cm)	LVIDd Avg; 2D and m-mode short axis (cm)	LVIDs Avg; 2D and m-mode short axis (cm)
NORMAL PARAMETER	50-100	0.7-1.7	0.7-1.6	BELOW	BELOW	BELOW	BELOW
PATIENT	140	1.6	1.1	32.1	4.9	5.6	3.6
*Normal chamber parameters expressed as a mean value (SD)				3	1.27 (5.3)	2.46 (2.46)	1.36 (5.5)
BODY WEIGHT DEPENDENT PARAMETERS				5	1.40 (4.5)	2.74 (5.2)	1.60 (4.7)
				10	1.50 (3.8)	3.27 (3.5)	2.06 (3.1)
				15	1.83 (2.0)	3.71 (2.4)	2.43 (2.1)
				20	2.02 (1.9)	4.14 (2.2)	2.80 (2.0)
				25	2.18 (2.4)	4.48 (2.9)	3.10 (2.5)
				30	2.33 (3.3)	4.83 (3.9)	3.39 (3.4)
				35	2.48 (4.3)	5.17 (5.0)	3.69 (4.5)
				40	2.62 (5.2)	5.48 (6.1)	3.96 (5.4)
				50	2.88 (7.1)	6.07 (8.3)	4.46 (7.4)

Adapted from June Boon, Veterinary Echocardiography, 1998
 Rishniw M and Hollis NE, J Vet Intern Med 2000; 14:429-435
 Hansson et al, Vet Rad and Ultrasound 2002
 Bonagura et al. Echocardiography: principles of interpretation, Vet Clin North Am 15:1177, 1995



PATIENT

Myles Marsh

SPECIES

Canine

BREED

Airdale

SEX

Male Neutered

AGE

10 years

WEIGHT

70.8lbs

INTERPRETED BY

Maggie Machen
Lamy, DVM, DACVIM
(Cardiology)

IMAGING PERFORMED BY

Jenna Walsh, CVT

HOSPITAL NAME

Four Corners
Veterinary Clinic

REFERRING VET

Dr. Dull

INVOICE

24566

DATE

6/3/22

INTERPRETATION OF THE FINDINGS & FURTHER RECOMMENDATIONS

The cause of the murmur is chronic degenerative valve disease causing severe mitral and mild to moderate tricuspid regurgitation. Severe left atrial enlargement indicates the risk for spontaneous congestive heart failure is elevated. No additional issues are identified. The ECG is unremarkable with a normal sinus rhythm.

In light of the clinical signs and severity of disease on echocardiogram, the diagnosis of congestive heart failure is suspected. **Baseline CXR are strongly recommended;** however, regardless of results, full cardiac support is recommended as below. Monitoring of sleeping respiratory rates will be paramount to screen for congestive heart failure at home. Cough suppression to improve QOL can also be considered (hydrocodone, 0.2-0.4mg/kg up to q4-6h PRN) for any residual mechanical cough in the face of normal sleeping respiratory rates. The average survival time of canine patients with active pulmonary edema is 8-9 months on medications, however they generally are able to maintain a good quality of life for that period. Patient will always be at risk for recurrent CHF, development of arrhythmias/LA tear, syncope and/or sudden death in the future.

Omega fatty acid supplementation and mild salt restriction may also be of some long-term benefit. Monitor for acute progression of the cough, labored breathing, exercise intolerance or collapse episodes in the future.

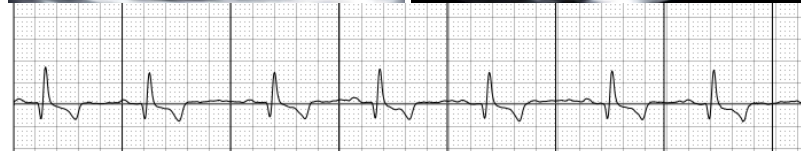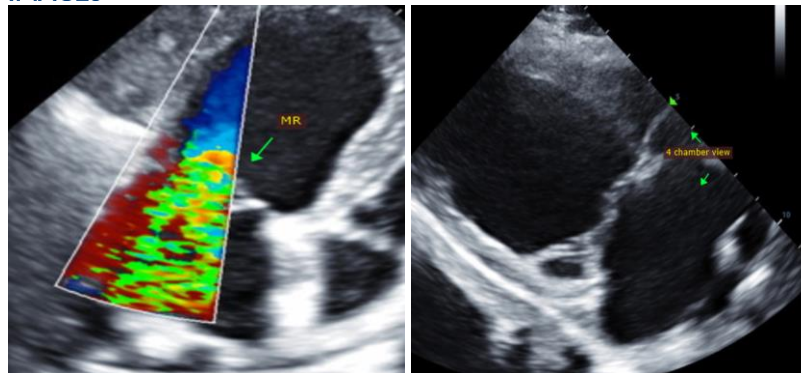
PLAN

Baseline CXR strongly recommended as discussed. Institute Pimobendan 0.3mg/kg PO q12h. Institute Furosemide 1-2mg/kg PO q12h. Institute spironolactone 1-2mg/kg PO q12h.

Monitor SRRs at home. Monitor renal values and BP in 10-14 days, then every 3-4 months while on diuretics. If doing well and BP >130mmHg, institute ACEI 0.5mg/kg PO q12h. Consider hydrocodone if needed for QOL.

Recommend conservative monitoring with a recheck echocardiogram in 6 months, sooner if any development of associated clinical signs occurs in the interim.

IMAGES





PATIENT

Myles Marsh

The information and recommendations provided are based on the images presented by the referring veterinarian. No evaluation can be communicated regarding pathology that was not visible in the image/video clips provided.

SPECIES

Canine

Thank you for this referral. This report was generated using transcription software, and minor dictation errors may be present. If the clinical or image interpretation does not parallel your findings or if I can be of any further assistance, please contact me.

BREED

Airdale

Maggie Machen Lamy, DVM
Diplomate of the American College of Veterinary Internal Medicine (Cardiology)
info@sonopath.com

SEX

Male Neutered

AGE

10 years

WEIGHT

70.8lbs

INTERPRETED BY

Maggie Machen
Lamy, DVM, DACVIM
(Cardiology)

**IMAGING
PERFORMED BY**

Jenna Walsh, CVT

HOSPITAL NAME

Four Corners
Veterinary Clinic

REFERRING VET

Dr. Dull

INVOICE

24566

DATE

6/3/22